

Laparoscopically assisted, ultrasound guided evacuation of a caesarean scar pregnancy

A. Makris, N. Bhuskute, C. Choy
 Calderdale & Huddersfield NHS Foundation Trust

We present the Ultrasound , MRI findings and surgical management of a female with a live caesarean scar pregnancy .

A 40 year old female, G6 P5 with two previous caesarean sections presented with an unplanned pregnancy, pain and bleeding. A transvaginal ultrasound scan was performed and identified a live caesarean scar ectopic pregnancy, 7w6d by CRL, likely type II. (Image 1) An MRI of her pelvis confirmed the U/S findings.(Image 2). Anterior myometrial thickness surrounding the pregnancy was one mm or less at it's thinnest point. Serum HCG was 120.000 mIU/ml .

The patient was counseled about her options. She was treated with systemic methotrexate and was planned for surgical management two days later. Our routine approach is U/S guided ERPC with additional haemostatic measures . However, in view of the very thin anterior myometrium there was concern about potential bladder injury during ERPC. Decision was taken do dissect the

bladder laparoscopically and perform ERPC under U/S guidance, with a plan to laparoscopically repair any uterine defects following ERPC.

On laparoscopy the patient was found to have a densely adherent bladder covering the caesarean scar pregnancy. (Image 3)The bladder was carefully dissected to the level of the vagina. (Image 4-5) A cervical suture was inserted, the pelvis was filled with normal saline to create an acoustic window (Image 6) and an ERPC was performed under U/S and laparoscopic guidance. Surprisingly there was no uterine perforation. A foley's catheter balloon was inflated in the lower segment. (Image 7-8) Estimated blood loss was 150 ml

The catheter and cervical suture were removed 48 hours postoperatively. The patient had an uneventful postoperative recovery with a sharp fall in the serum HCG 48 hours postoperatively.

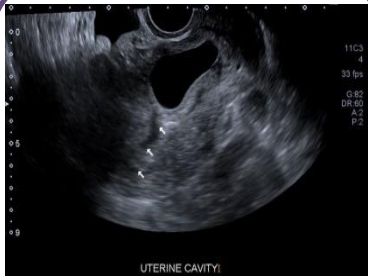

Image 1

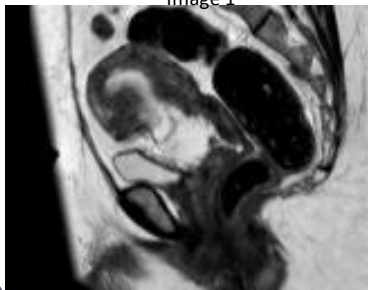


Image 2

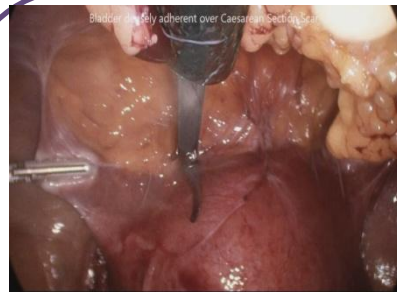

Image 3

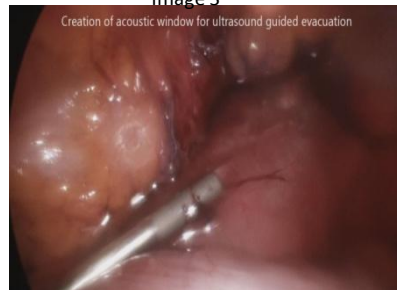

Image 6

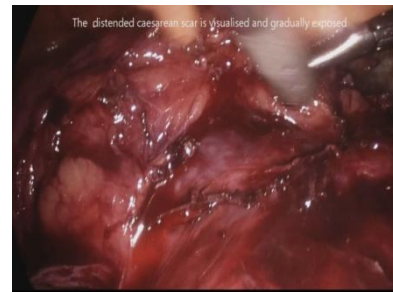


Image 4

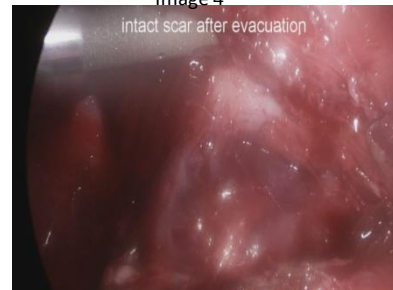

Image 7

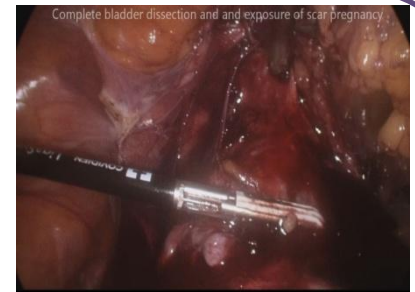


Image 5

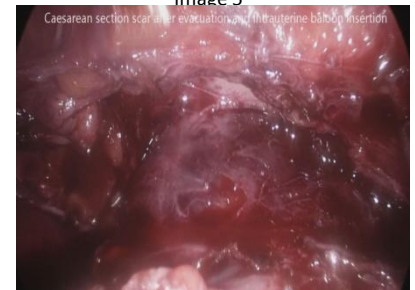


Image 8