

Samaritana University Hospital - Bogota - Colombia

R. Duque¹, L. Enciso², G. Reyes³, G. Arias⁴, A. Velasco⁴, L. Amórtegui⁴, A. Vásquez⁴, J. Farfán⁴, A. Covo⁴, R. Gallo¹

1. Obstetric and gynaecology Consultant

2. Haematology Consultant

3. Maternal Fetal Medicine Consultant

4. Resident HUS

Zyka virus-associated hemophagocytic syndrome during pregnancy



Introduction

Hemophagocytic lymphohistiocytosis syndrome (HLH) is an unusual aggressive and life-threatening syndrome of excessive immune activation. HLH can occur as a familial or sporadic disorder, and it can be triggered by a variety of events that disrupt immune homeostasis. Infection is a common trigger both in those with a genetic predisposition and in sporadic cases. Prompt initiation of treatment is essential for the survival of affected patients.

During pregnancy is very rare. There are a few cases of HLH reported during the pregnancy. Infection is the most frequent cause, virus infection almost all of them and autoimmune diseases was the second cause. Up to date, this is one of the first reports of zyka virus-associated hemophagocytic syndrome during pregnancy.

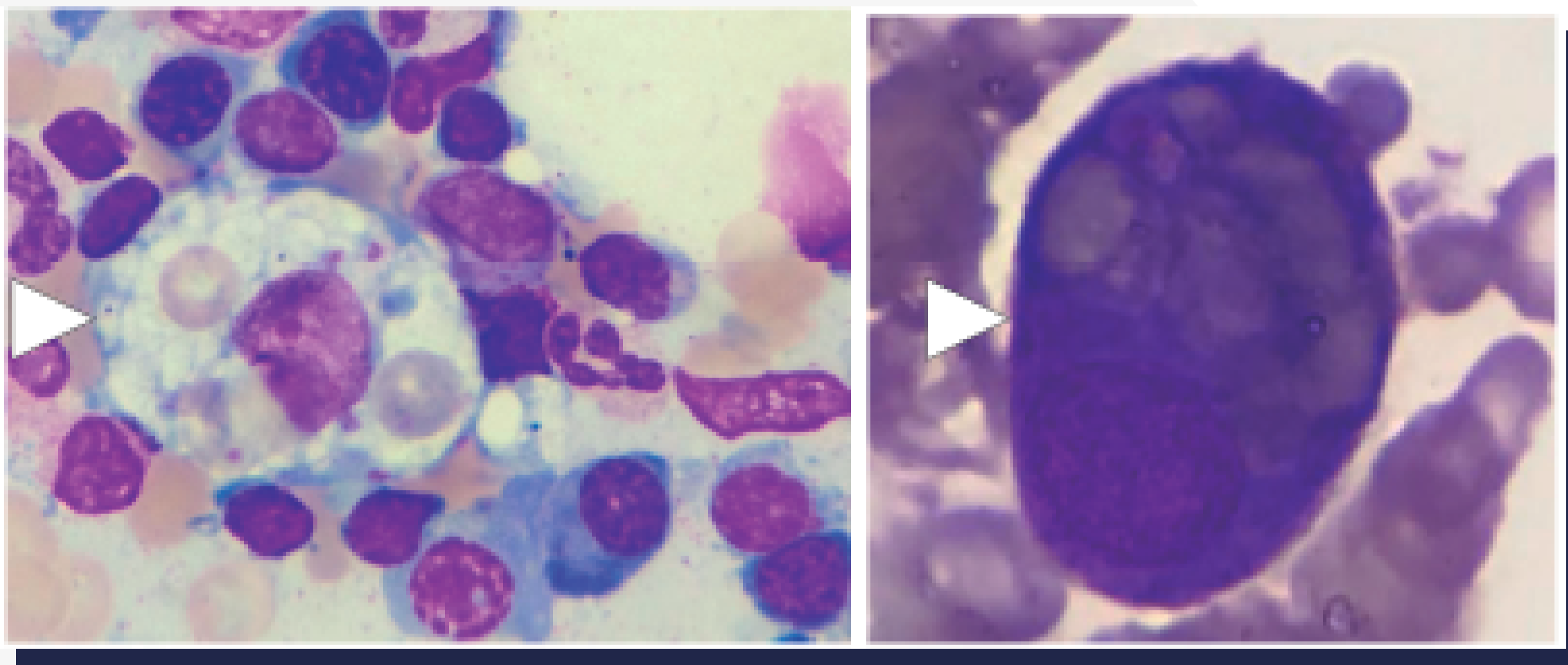
Case

A 25-year-old patient, G2P1V1, with a 10 weeks pregnancy, with one week fever (39.7o C) maculopapular rash and arthralgia. Elevated liver function tests: AST(344), ALT(443) and LDH(944). Ultrasound showed hepatosplenomegaly. Test for Dengue, CMV, EBV, herpes, HIV and autoimmunity were negative. Myelogram showed Hemophagocytosis in bone marrow biopsy. Five criteria of HLH were found and treatment with dexamethasone was started with clinical improvement. PCR test for the Zika virus was positive.

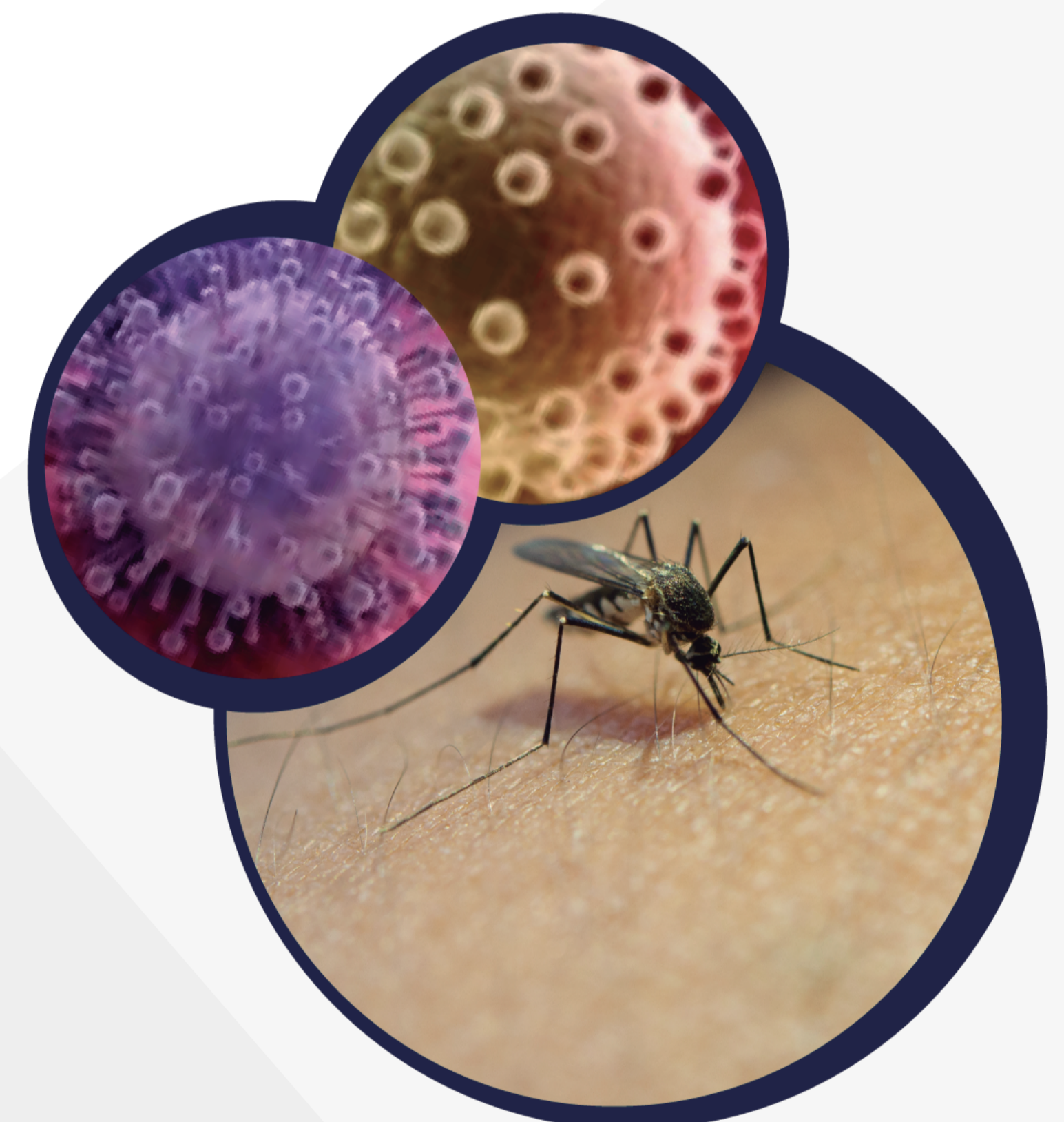
Conclusion

Hemophagocytic syndrome is an unusual aggressive and life-threatening syndrome. During pregnancy is very rare. There are a few cases of HLH reported during the pregnancy. Infection is the most frequent cause, virus infection almost all of them and autoimmune diseases was the second cause. Up to date, this is one of the first reports of zyka virus-associated hemophagocytic syndrome during pregnancy.

A high diagnostic suspicion, appropriate complementary tests and prompt initiation of treatment is essential for the survival of patients.



Myelogram showed Hemophagocytosis in bone marrow biopsy (arrows)



Copyright - Microcosm Medical Medical Animation 2016 / NBCNEWS.COM / www.treepik.com/terms_of_use