

# Midbrain and Falx in Fetuses with Absent Corpus Callosum at 11–13 Weeks

Robert Lachmann<sup>a-c</sup> Danielle Sodre<sup>b, c</sup> Michail Barmpas<sup>b, c</sup> Ranjit Akolekar<sup>c</sup>  
Kypros H. Nicolaides<sup>b, c</sup>

<sup>a</sup>Department of Obstetrics and Gynecology, University Hospital Carl Gustav Carus, Dresden, Germany;

<sup>b</sup>Department of Fetal Medicine, University College Hospital, and <sup>c</sup>Harris Birthright Research Centre for Foetal Medicine, King's College Hospital, London, UK

## Key Words

First-trimester screening · Absent corpus callosum · Nonchromosomal abnormalities · Midsagittal view · Nuchal translucency

## Abstract

**Objective:** To describe the first trimester diagnosis of agenesis of the corpus callosum (ACC). **Methods:** The midbrain and falx cerebri were examined in stored images of the midsagittal view of the fetal brain at 11<sup>+0</sup>–13<sup>+6</sup> weeks' gestation from 15 fetuses with ACC and 500 normal controls. The midbrain diameter and falx diameter were measured and their ratio was calculated. The values in fetuses with ACC and normal controls were compared. **Results:** In the control group, the midbrain and falx diameters increased significantly with crown-rump length (CRL) from respective mean values of 5.1 and 6.9 mm at CRL of 45–6.9 mm and 12.1 mm at CRL of 84 mm. In the ACC group the midbrain diameter was above the 95th percentile of the control group in 8 (53.3%) cases, the falx diameter was below the 5th percentile in 6 (40.0%) cases and the midbrain diameter-to-falx diameter ratio was above the 95th percentile in 13 (86.7%) cases. **Conclusions:** In the midsagittal view of the fetal brain at 11–13 weeks, the majority of fetuses with ACC have measurable abnormalities in the midbrain and falx area of the brain.

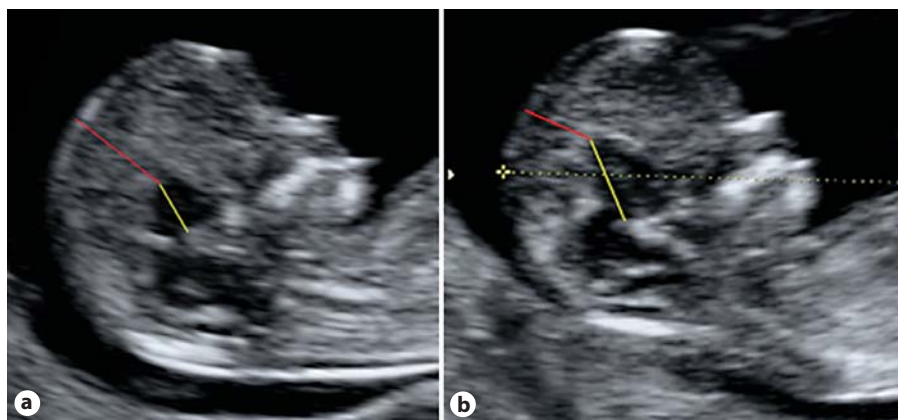
Copyright © 2012 S. Karger AG, Basel

## Introduction

Agenesis of the corpus callosum (ACC), which may be either complete or partial, is found in about 1 per 4,000 births and it is commonly associated with aneuploidies and more than 50 genetic syndromes [1, 2]. Prenatal diagnosis is confined to the second and third trimesters of pregnancy and relies on failure to demonstrate the corpus callosum itself in both the midsagittal and coronal views of the brain [3]. The condition is suspected by absence of the cavum septum pellucidum between 18 and 37 weeks and the teardrop configuration of the lateral ventricles with enlargement of the posterior horns [3]. In a screening study at 11–13 weeks' gestation of more than 45,000 pregnancies, none of the 10 cases of ACC was suspected or diagnosed at this gestational age [4].

The corpus callosum is the largest commissure connecting the cerebral hemispheres.

It results from an interhemispheric fusion line with groups of glial cells channelling the commissural axons through the interhemispheric meninges towards the contralateral hemispheres. The anterior callosum and the splenium fuse to form the complete commissural plate [5]. Development of the corpus callosum takes place between 12 and 18 weeks of gestation. The corpus callosum is closely related both anatomically and embryologically with the underlying septum pellucidum. The corpus cal-



**Fig. 1.** Midsagittal view of the fetal brain demonstrating the measurements of mid-brain diameter and falx diameter in a normal fetus (a) and a fetus with absent corpus callosum (b).

losum is a thin band of white matter and its sonographic demonstration requires adequate angles of insonation. Only midsagittal and midcoronal scans of the fetal brain usually allow clear visualization [5, 6].

In 1937, Hyndman and Penfield [7] described that in patients with ACC there is enlargement and cranial displacement of the third cerebral ventricle. The aim of this study was to develop a method of assessing the position of the third ventricle in the midsagittal view of the fetal brain at 11–13 weeks' gestation and investigate the potential for first trimester diagnosis of ACC.

## Methods

This was a case-control study of stored images of the midsagittal view of the fetal brain at 11–13 weeks' gestation. At King's College Hospital and University College London Hospital, London, UK, all women undergoing routine pregnancy care have an ultrasound scan at 11–13 weeks' gestation as part of a combined screening for aneuploidies and another scan for fetal anatomy and growth at 20–24 weeks [8]. We searched the databases of these hospitals to identify cases of ACC diagnosed during the second trimester of pregnancy which had stored images of the midsagittal view of the fetal brain at 11<sup>+0</sup>–13<sup>+6</sup> weeks of gestation. The retrospectively collected stored images of the 500 control cases were of 500 examined pregnancies at 11<sup>+0</sup>–13<sup>+6</sup> weeks in which detailed ultrasound examination at 20–24 weeks showed no fetal abnormalities.

The stored images of the midsagittal view of the fetal brain of the cases of ACC and controls were placed in the same folder and were examined by a sonographer with extensive experience in first-trimester scanning who had obtained the Fetal Medicine Foundation Certificate of Competence in the 11–13 weeks scan. This sonographer, who was unaware of the pregnancy outcomes, examined the brain and used the Software IQ-View 2.70b (Image Information Systems, Rostock, Germany) to measure the diameters of the midbrain and falx. In the midsagittal view of the fetal brain the midbrain essentially consists of the thalamus and third

ventricle visualised as a single hypoechoic area (fig. 1). The mid-brain diameter was the maximum distance between the posterior portion of the upper border of the sphenoid bone behind the sella turcica and the border between the hypoechoic midbrain and the echogenic falx. The falx diameter was the minimum distance between the border of the hypoechoic midbrain area with the echogenic falx caudally and the skin of the fetal head cranially.

The ratio between midbrain diameter and falx diameter was calculated.

The agreement and bias for the measurements of midbrain diameter and falx diameter by a single examiner and between two different examiners was investigated from the study of 50 images which were selected at random from the database. One operator (A) who made the original measurements repeated the measurements in the series of 50 pictures, and a second operator (B) made the measurements once. The operators were not aware of the measurements of each other, and operator A when making the measurements on the second occasion was not aware of his measurements on the first occasion.

### Statistical Analysis

In the control group, regression analysis was used to construct reference ranges with fetal crown-rump length (CRL) for mid-brain diameter, falx diameter, and midbrain diameter-to-falx diameter ratio. In each fetus in both the ACC and control groups the measured diameters and their ratio were subtracted from the respective normal mean for CRL to calculate the delta value. The Kolmogorov-Smirnov test demonstrated that the distribution of delta values of the two measurements and their ratio was Gaussian in both the ACC and control groups. An independent samples t test was used to determine the significance of differences in the mean delta values between the groups. Bland Altman analysis was used to examine the degree of agreement and bias between measurements by a single operator and two different operators for midbrain diameter and falx diameter [9]. A paired t test was used to compare the significance of differences between these paired measurements.

The statistical software package SPSS 19.0 (IBM SPSS, Chicago, Ill., USA) was used for data analysis.

**Table 1.** Outcomes, karyotypes, and abnormal ultrasound findings of the cases with ACC

No.	Karyotype	Outcome	US/MRI/postmortem	Abnormal ultrasound findings
1	46XY	TOP	US	Teardrop sign, not visible cavum septum pellucidum, enlarged third ventricle, hydrops, Ebstein's anomaly
2	46XX	TOP	US, postmortem	Teardrop sign, not visible cavum septum pellucidum
3	Male phenotype, karyotype not known	TOP	US, MRI	Teardrop sign, not visible cavum septum pellucidum
4	Female phenotype, karyotype not known	TOP	US, MRI, postmortem	Teardrop sign, cerebellar vermian agenesis (partial)
5	Male phenotype, karyotype not known	TOP	US, MRI	Teardrop sign, not visible cavum septum pellucidum
6	46XY	TOP	US	Teardrop sign, not visible cavum septum pellucidum, FGR, rocker bottom feet, polydactyly, hypoplastic cerebellum
7	46XY	TOP	US	Teardrop sign, not visible cavum septum pellucidum, severe lethal skeletal dysplasia, cloverleaf skull, ventriculomegaly, DWM (complete)
8	Not known	TOP	US, MRI	Teardrop sign, not visible cavum septum pellucidum, malformation of the insula, migration disorder, dilated third ventricle
9	46XX	TOP	US	Teardrop sign, not visible cavum septum pellucidum, enlarged third ventricle
10	46XY	Live-born, 2,890 g, 40 weeks + 2 days	US, MRI	Teardrop sign, not visible cavum septum pellucidum
11	46XX	TOP	US, MRI	Teardrop sign, not visible cavum septum pellucidum, ventriculomegaly, enlarged third ventricle
12	Not known	TOP	US, MRI	Teardrop sign, not visible cavum septum pellucidum, enlarged third ventricle
13	46XX + FGFR3 thanato-phoric dysplasia	IUFD	US	From 16 weeks on enlarged third ventricle, teardrop sign, not visible cavum septum pellucidum
14	Monosomy 4p (Wolf-Hirschhorn syndrome)	TOP	US, postmortem	Hypertelorism, abnormal facial profile, teardrop sign, not visible cavum septum pellucidum
15	Trisomy 22, male	TOP	US, postmortem	Abnormal facial profile, hypertelorism, ventriculomegaly, teardrop sign, not visible cavum septum pellucidum

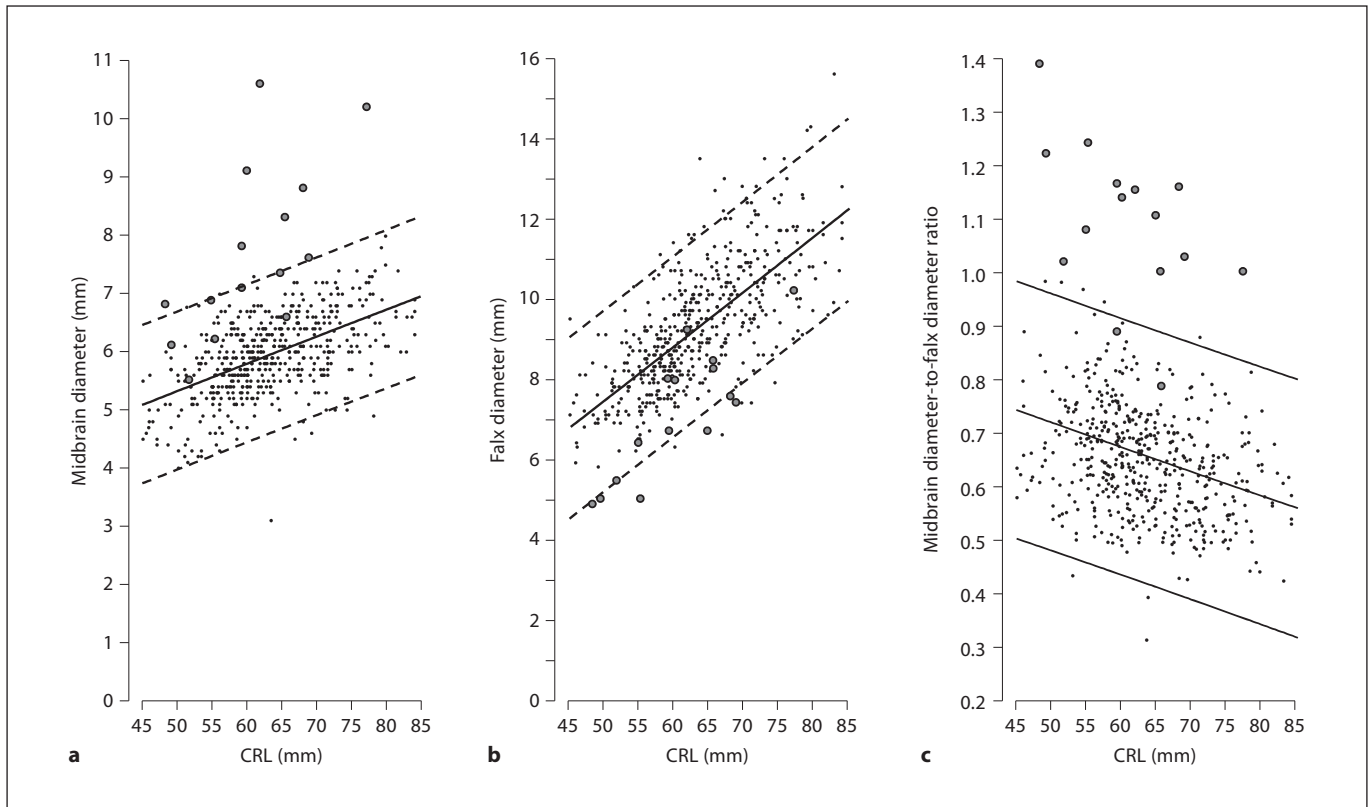
TOP = Termination of pregnancy, IUFD = intrauterine fetal death, US = ultrasound, MRI = magnetic resonance imaging.

## Results

In the search of the database for ACC we identified 20 cases diagnosed in the second trimester, but there were only 15 in which the images obtained at 11–13 weeks were of sufficiently good quality to allow assessment of the midbrain. The ACC cases were examined between De-

cember 2000 and August 2011 and the control cases were examined between July 2008 and March 2011.

The median CRL at the time of the first-trimester scan was 62 mm (range 45–84) for the controls and 60 mm (range 48–77) for the cases of ACC. The diagnosis of ACC, which was complete in all cases, was made at a median of 23 weeks' gestation (range 20–27 weeks).



**Fig. 2.** Individual measurements of midbrain diameter (a), falx diameter (b), and midbrain diameter-to-falx diameter ratio (c) in fetuses with absent corpus callosum (open circles) and normal controls (closed circles) plotted on the appropriate reference range for CRL (median, 5th and 95th centiles).

**Table 2.** Comparison of the mean delta values and standard deviation (SD) of midbrain diameter, falx diameter, and the ratio of midbrain diameter to falx diameter in fetuses with ACC and normal controls

Measurement	Control	ACC	p value
Mean delta midbrain diameter (SD)	0.000 (0.303)	1.297 (0.420)	<0.0001
Mean delta falx diameter (SD)	0.000 (0.468)	-1.772 (0.677)	<0.0001
Mean delta MD-to-FD ratio (SD)	0.000 (0.081)	0.769 (0.265)	<0.0001

Abnormal ultrasound findings, karyotypes, and outcomes are shown in table 1. In the control group, there was a significant increase with CRL in midbrain diameter ( $2.9539 + 0.04689 \times \text{CRL}$  in mm, SD 0.58,  $R^2 = 0.299$ ; fig. 2) and falx diameter ( $0.9004 + 0.1331 \times \text{CRL}$  in mm, SD 1.124,  $R^2 = 0.487$ ; fig. 2) and a decrease in the midbrain diameter-to-falx diameter ratio ( $0.8989 - 0.0040 \times \text{CRL}$ , SD 0.10,  $R^2 = 0.101$ ; fig. 2).

In the fetuses with ACC, compared to the normal controls, the mean midbrain diameter was significantly in-

creased and it was above the 95th percentile of the reference range for CRL in 8 (53.3%) of the 15 cases (table 2; fig. 2). The mean falx diameter was significantly decreased and it was below the 5th percentile in 6 (40%) cases. The mean midbrain diameter-to-falx diameter ratio was significantly increased and it was above the 95th percentile in 13 (86.7%) cases. In all these 13 cases of ACC the ratio was more than 1, whereas in all normal cases the ratio was less than 1.

**Table 3.** Mean differences and 95% LOA (bold numbers in parentheses) with their 95% CI (numbers in square brackets) between 50 paired measurements by the same sonographer and between 50 paired measurements by two sonographers in midbrain diameter and falx diameter

Measurement	Mean difference (95% LOA) [95% CI]
Midbrain diameter	
Interobserver	-0.012 (- <b>0.977</b> [-1.119 to -0.835], <b>0.953</b> [0.811 to 1.095])
Intraobserver	-0.004 (- <b>0.345</b> [-0.487 to -0.203], <b>0.337</b> [0.195 to 0.479])
Falx diameter	
Interobserver	-0.030 (- <b>1.180</b> [-1.322 to -1.038], <b>1.120</b> [0.978 to 1.262])
Intraobserver	-0.022 (- <b>0.545</b> [-0.687 to -0.403], <b>0.501</b> [0.359 to 0.643])

### *Intraobserver Variability*

The bias (mean difference) and 95% limits of agreement (LOA) between paired measurements of midbrain diameter by the same operator are shown in table 2. A paired t test to assess the repeatability of measurements demonstrated that there was no significant difference in the measurement of either midbrain diameter ( $p = 0.871$ ) or falx diameter ( $p = 0.562$ ). The Pearson correlation coefficient between the difference and the mean of measurements by the same operator for midbrain diameter was 0.168 (95% CI -0.116 to 0.426) and for falx diameter it was 0.126 (95% CI -0.157 to 0.391). There was no significant change with gestation in the intraobserver agreement in paired measurements (midbrain diameter:  $r = 0.061$ ,  $p = 0.673$ ; falx diameter:  $r = -0.194$ ,  $p = 177$ ).

### *Interobserver Variability*

The bias (mean difference) and 95% LOA between paired measurements of midbrain and falx diameters by two different operators are shown in table 3. A paired t test to assess the repeatability of measurements demonstrated that there was no significant difference in the measurement of either midbrain diameter ( $p = 0.864$ ) or falx diameter ( $p = 0.719$ ). The Pearson correlation coefficient between the difference and the mean of measurements by two different operators for midbrain diameter was 0.368 (95% CI 0.099–0.586) and for falx diameter it was 0.024 (95% CI -0.256 to 0.300). There was no significant change with gestation in the interobserver agreement in paired measurements (midbrain diameter:  $r = 0.093$ ,  $p = 0.520$ ; falx diameter:  $r = 0.032$ ,  $p = 0.825$ ).

### **Discussion**

The findings of this study demonstrate that in the midsagittal view of the fetal brain at 11–13 weeks' gestation the midbrain and falx diameters normally increase and their ratio decreases with CRL. In fetuses with ACC, compared to normal fetuses, the midbrain diameter is higher, the falx diameter is lower, and the midbrain diameter-to-falx diameter ratio is higher. In our study of stored images of the midsagittal view of the fetal brain it was not possible to distinguish between the third ventricle and the thalamus, and it was therefore decided to take a single measurement of the thalamo-ventricular complex. The findings are compatible with the original description of adults with ACC [7] and suggest that the condition is associated with enlargement and cranial displacement of the third ventricle which are apparent from the first trimester of intrauterine life.

However, there could be an additional bias due to the fact that ACC cases were examined over a much longer time period than the 500 control cases. The examination date, which is provided on all images, could suggest an adverse pregnancy outcome.

An inevitable limitation of this study is that, although the sonographer performing the measurements was unaware of the pregnancy outcomes, the suspicion of a brain anomaly would have been raised by the presence of an abnormal appearance of the thalamo-ventricular complex which could have introduced a bias in the measurements, and that electronically stored images were used. However, there was a clear difference in measurements between normal and affected fetuses. The midbrain diameter-to-falx diameter ratio was almost always smaller in normal fetuses and the opposite was true in 87% of the fetuses with ACC. In the midsagittal plane, measurements of the midbrain diameter and the falx diameter



were highly reproducible and in about 95% of cases the values of two measurements by the same observer or measurements by different observers were within 3% of each other.

Examination of the midsagittal view of the fetal brain at 11–13 weeks is performed routinely for assessment of fetal nuchal translucency and nasal bone in screening for aneuploidies [8]. In this same view the posterior brain can be examined and demonstration of dilation of the brain stem with a decrease in the diameter of the fourth ventricle and cisterna magna can lead to the early diagnosis of open spina bifida [10–12]. The findings of our study suggest that in the same midsagittal view of the brain there are measurable abnormalities in the midbrain and falx which could raise the possibility of an underlying

ACC. These findings require validation from prospective studies which will also determine whether a definitive diagnosis of ACC could be made at 11–13 weeks or the finding of an increase in the midbrain diameter-to-falx diameter ratio should act as a warning sign requiring further investigation by neurosonography at 18 weeks when the current criteria for diagnosis of ACC [3] would be applied.

### Acknowledgement

This study was supported by a grant from the Fetal Medicine Foundation (charity No. 1037116).

### References

- 1 Glass HC, Shaw GM, Ma C, Sherr EH: Agenesis of the corpus callosum in California 1983–2003: a population-based study. *Am J Med Genet* 2008;146A:2495–2500.
- 2 Paul LK, Brown WS, Adolphs R, Tyszka JM, Richards LJ, Mukherjee F, Sherr EH: Agenesis of the corpus callosum: genetic, developmental and functional aspects of connectivity. *Nat Rev Neurosci* 2007;8:287–299.
- 3 Pilu G, Sandri F, Perolo A, Pittalis MC, Grisolia G, Cocchi G, Foschini, MP, Salvioli, GP, Bovicelli L: Sonography of fetal agenesis of the corpus callosum: a survey of 35 cases. *Ultrasound Obstet Gynecol* 1993;3:318–329.
- 4 Syngelaki A, Chelemen T, Dagklis T, Allan L, Nicolaides KH: Challenges in the diagnosis of fetal non-chromosomal abnormalities at 11–13 weeks. *Prenat Diagn* 2011;31:90–102.
- 5 Raybaud C: The corpus callosum, the other great forebrain commissures, and the septum pellucidum: anatomy, development and malformation. *Neuroradiology* 2010;52:447–477.
- 6 Plasencia W, Dagklis T, Borenstein M, Csapo B, Nicolaides KH: Assessment of the corpus callosum at 20–24 weeks' gestation by three-dimensional ultrasound examination. *Ultrasound Obstet Gynecol* 2007;30:169–172.
- 7 Hyndman M, Penfield HR: Agenesis of the corpus callosum: its recognition by ventriculography. *Arch Neur* 1937;37:1251–1270.
- 8 Nicolaides KH: Screening for fetal aneuploidies at 11 to 13 weeks. *Prenat Diagn* 2011;31:7–15.
- 9 Bland JM, Altman DG: Statistical methods for assessing agreement between two methods of clinical measurement. *Lancet* 1986;1:307–310.
- 10 Chaoui R, Benoit B, Mitkowska-Wozniak H, Heling KS, Nicolaides KH: Assessment of intracranial translucency (IT) in the detection of spina bifida at the 11–13-week scan. *Ultrasound Obstet Gynecol* 2009;34:249–252.
- 11 Lachmann, R, Chaoui, R, Moratalla, J, Picciarelli, G, Nicolaides KH: Posterior brain in fetuses with open spina bifida at 11 to 13 weeks. *Prenat Diagn* 2011;31:103–106.
- 12 Chaoui R, Nicolaides KH: Detecting open spina bifida at the 11–13-week scan by assessing the posterior brain region: mid-sagittal or axial plane? *Ultrasound Obstet Gynecol* 2011;38:609–612.