

3. Krebs HB. Prophylactic topical 5-fluorouracil following treatment of human papillomavirus-associated lesions of the vulva and vagina. *Obstet Gynecol* 1986;68:837-41.
4. Reid R, Greenberg MD, Lorincz AT, et al. Superficial laser vulvectomy. IV. Extended laser vaporization and adjuvant 5-fluorouracil therapy of human papillomavirus associated vulvar disease. *Obstet Gynecol* 1990;76:439-48.
5. Trofatter KF. Interferon. *Obstet Gynecol Clin North Am* 1987;14:569-79.
6. Turek L, Byrne JC, Lowy DR, et al. Interferon induces morphologic reversion with elimination of extrachromosomal viral genomes in bovine papillomavirus transformed mouse cells. *Proc Natl Acad Sci U S A* 1982;79:7914-8.
7. Gall SA, Hughes CE, Trofatter K. Interferon for the therapy of condyloma acuminatum. *AM J OBSTET GYNECOL* 1985;153:157-63.
8. Gall SA, Hughes CE, Mounts P, et al. Efficacy of human lymphoblastoid interferon in the therapy of resistant condyloma acuminata. *Obstet Gynecol* 1986;67:643-51.
9. Schonfeld A, Schattner A, Crespi M, et al. Intramuscular human interferon-beta injections in treatment of condylomata acuminata. *Lancet* 1984;1:1038-41.
10. Kirby P, Kiviat N, Beckman A, Wells D, Sherwin S, Corey L. Tolerance and efficacy of recombinant human "interferon" gamma in the treatment of refractory genital warts. *Am J Med* 1988;85:183-8.
11. Reichman RC, Oakes D, Bonnez W, et al. Treatment of condyloma acuminatum with three different interferon-alpha preparations administered parenterally: a double-blind, placebo-controlled trial. *J Infect Dis* 1990;162:1270-6.
12. Kirby P. Interferon and genital warts: much potential, modest progress. *JAMA* 1988;259:570-2.
13. Reid R, Dorsey JH. The physical and surgical principles of carbon dioxide laser surgery in the lower genital tract. In: Coppleson M, Monaghan J, Morrow CP, Tattersall MHR, eds. *Gynecologic oncology. Theoretical basis and practical principles*. Edinburgh: Churchill Livingstone, 1991:1093-137.
14. Vesterinen E, Meyer B, Purola E, et al. Treatment of vaginal flat condyloma with interferon cream. *Lancet* 1984;1:157-8.
15. Friedman-Kien AE, Eron LJ, Conant M, et al. Natural interferon alpha for treatment of condylomata acuminata. *JAMA* 1988;259:533-8.
16. Lorincz AT, Reid R, Jensen AB. Human papillomavirus infection of the cervix: relative risk associations of 15 common anogenital types. *Obstet Gynecol* 1992;79:328-37.

---

## Therapeutic amniocentesis in twin-twin transfusion syndrome appearing in the second trimester of pregnancy

N.J. Saunders, MD, R.J.M. Snijders, MSc, and K.H. Nicolaides, MD

London, England

Amniocentesis and drainage were performed in 19 twin pregnancies initially seen at <28 weeks' gestation with acute polyhydramnios caused by the twin-twin transfusion syndrome. The procedure was performed an average of three times for each patient (range one to six), with the removal of a mean volume of amniotic fluid of 2600 ml on each occasion (range 500 to 6700 ml). The interval between initial examination and delivery averaged 7 weeks (range 1 day to 18 weeks); 14 (37%) of the 38 babies survived the neonatal period. In the pregnancies with poor outcomes, the intertwin disparity in fetal size and the mean volume of amniotic fluid drained at each amniocentesis were greater than in the pregnancies in which one or both twins survived. (*AM J OBSTET GYNECOL* 1992;166:820-4.)

**Key words:** Twin-twin transfusion syndrome, amniocentesis, amniotic fluid drainage, polyhydramnios, ultrasonography

*From The Harris Birthright Research Centre for Fetal Medicine, King's College Hospital School of Medicine.*

*Received for publication May 3, 1991; revised September 18, 1991; accepted September 30, 1991.*

*Reprint requests: K.H. Nicolaides, MD, The Harris Birthright Research Centre for Fetal Medicine, King's College Hospital School of Medicine, Denmark Hill, London SE5 8RX, England.*

*6/1/34063*

In twin pregnancies with presumed twin-twin transfusion syndrome, development of acute polyhydramnios at <28 weeks' gestation is associated with a high perinatal mortality rate, primarily because of spontaneous abortion or very premature delivery of growth-retarded babies or babies with hydrops. In an analysis

**Table I.** Fetal survival in twin pregnancies initially seen with acute polyhydramnios at <28 weeks' gestation and managed conservatively or by amniocentesis

<i>Management</i>			
<i>Conservative</i>		<i>Amniocentesis</i>	
<i>Author</i>	<i>Survival rate</i>	<i>Author</i>	<i>Survival rate</i>
Chescheir and Seeds (1988) <sup>1</sup>	0/4	Bebbington and Wittmann (1989) <sup>9</sup>	0/6
Brown et al. (1989) <sup>2</sup>	1/8	Chescheir and Seeds (1988) <sup>1</sup>	0/6
Elejalde et al. (1983) <sup>3</sup>	0/2	Feingold et al. (1986) <sup>10</sup>	1/2
Patten et al. (1989) <sup>4</sup>	3/48	Brennan et al. (1982) <sup>11</sup>	1/2
Pretorius et al. (1988) <sup>5</sup>	1/14	Brown (1958) <sup>12</sup>	1/2
Urig et al. (1990) <sup>6</sup>	0/10	Brown (1980) <sup>13</sup>	2/2
Weir et al. (1979) <sup>7</sup>	0/16	Brown and Macaskill (1961) <sup>14</sup>	2/2
Wittmann et al. (1981) <sup>8</sup>	0/4	Danziger (1948) <sup>15</sup>	1/2
		Erskine (1944) <sup>16</sup>	1/2
		Gonsoulin et al. (1990) <sup>17</sup>	4/22
		Mills (1980) <sup>18</sup>	2/2
		Montan et al. (1985) <sup>19</sup>	2/4
		Nageotte et al. (1989) <sup>20</sup>	2/4
		Schneider et al. (1985) <sup>21</sup>	8/20
		Urig et al. (1990) <sup>6</sup>	6/18
<b>TOTAL</b>	<b>5/106</b>		<b>33/96</b>

**Table II.** Outcome of twin pregnancies initially examined with acute polyhydramnios and intrauterine death of one of the fetuses at <28 weeks' gestation

<i>Gestation at presentation (wk)</i>	<i>Dead fetus</i>	<i>Condition of surviving fetus</i>	<i>Outcome of pregnancy</i>	<i>wk</i>
20	Donor	Ventriculomegaly	TOP	20
19	Recipient	Hydrops	SA	20
21	Donor	Hydrops	LB	33
23	Donor	Normal	LB	32
27	Recipient	Normal	LB	37

TOP, Termination of pregnancy; SA, spontaneous abortion; LB, live birth.

of 51 such published cases in which no antenatal intervention was undertaken, only five babies survived (Table I). Several reports on a small number of patients have suggested that outcome may be improved by repeated amniocenteses; therefore during the last 3 years a systematic prospective study was undertaken to examine the possible efficacy of this approach.

**Patients and methods**

During a 3-year period (1988 to 1990) 27 twin pregnancies with polyhydramnios at <28 weeks' gestation were referred to our unit for prenatal diagnosis and management. Ultrasonographic examination demonstrated that the fetuses were discordant in size and were separated by a thin membrane; there was a single placenta. In each case the larger twin was surrounded by polyhydramnios and appeared to have a distended bladder. The smaller twin appeared to be fixed to the placenta because of oligohydramnios, and no bladder could be found.<sup>22</sup>

In five cases one of the twins was dead at initial examination, and the surviving cotwin had either ventriculomegaly ( $n = 1$ ) or hydrops ( $n = 2$ ) or was normal ( $n = 2$ ). The outcome of these pregnancies is shown in Table II. In another case initially seen at 21 weeks the recipient twin was normal, but the donor had ventriculomegaly. The pregnancy was managed conservatively and resulted in a spontaneous abortion at 22 weeks. Postmortem examination demonstrated intraventricular hemorrhage in the donor twin.

In the remaining 21 patients both fetuses were normal. The parents were counseled as to the likely poor prognosis and offered the options of conservative management, decompression amniocentesis, or termination of pregnancy. One patient opted for conservative management and miscarried 1 week after examination; another requested termination of pregnancy. The other 19 patients consented to serial amniocenteses. Ultrasonographically guided amniocentesis was performed with an 18-gauge needle, and amniotic fluid was al-

**Table III.** Gestational age at amniocentesis, volume of amniotic fluid, drained, pregnancy outcome, intertwin difference in abdominal circumference at initial examination

Case No.	Volume drained (L)										
	At $\leq 20$ wk	At 21 wk	At 22 wk	At 23 wk	At 24 wk	At 25 wk	At 26 wk	At 27 wk	At 28 wk	At 29 wk	At $\geq 30$ wk
1	—	—	—	6.7	—	—	—	—	—	—	—
2	—	—	—	2.5	—	—	—	—	—	—	—
3	—	—	—	3.0	2.4	—	—	—	—	—	—
4	—	—	—	3.2	4.0	—	—	—	—	—	—
5	1.0	—	—	—	—	—	—	—	—	—	—
6	—	—	—	2.5	2.3	—	3.0	—	—	—	—
7	—	—	3.5	—	—	0.5	—	—	—	—	—
8	—	4.0	2.0	1.7	2.0	—	—	—	3.0	—	—
9	—	—	5.0	—	—	—	—	4.9	4.6	6.0	—
10	—	—	4.0	—	3.5	—	1.5	3.5	—	3.0	—
11	—	—	3.0	2.8	1.0	2.5	—	—	—	—	—
12	—	—	—	—	1.5	—	—	3.7	—	—	—
13	—	—	2.1	—	—	—	—	—	—	—	—
14	—	—	—	—	—	—	3.0	3.0	1.5	4.3	3.2
15	—	3.2	—	1.5	—	3.2	—	1.9	—	—	—
16	—	4.5	—	—	2.4	3.3	—	2.8	—	—	—
17	0.6	0.5	—	—	—	—	—	—	—	—	—
18	1.0	3.0	—	3.0	—	—	—	3.0	—	3.0	—
19	1.0	1.5	1.0	1.0	1.0	1.5	—	—	—	—	—

SA, Spontaneous abortion; IUD, intrauterine death; NND, neonatal death; LB, live-born survivor.

\*Died at 6 months.

lowed to drain freely into a sterile bag through a plastic tube attached to the hub of the needle. In each case 500 to 6700 ml was drained over a period of 40 to 120 minutes until there was subjective normalization of amniotic fluid volume on ultrasonographic examination. Patients were assessed every week; if they had symptoms or if the abdomen was considered to be tense on palpation, further drainage was performed.

### Results

For the 19 patients who had amniocentesis, the gestation at examination, volume of amniotic fluid drained, and outcome are summarized in Table III. The mean gestation at initial examination was 21 weeks 5 days (range 17 to 25). Amniocenteses were performed one to six times (mean three) with the average removal of 2600 ml of amniotic fluid at each tap (range 500 to 6700 ml). The mean interval between initial examination and delivery was 6.5 weeks (range 1 day to 18 weeks).

Four patients (Table III; cases 1 through 4) aborted spontaneously within 48 hours of the first or second drainage procedures. In six patients (Table III; cases 5 through 10), amniocentesis and relief of polyhydramnios were associated with prolongation of pregnancy by 2 to 9 weeks, but either both babies died in utero or the death of one fetus was associated with deterioration in the condition of the second twin, who was delivered but died in the neonatal period. In four cases (Table III; cases 11 to 14) one infant survived, but the

other twin died either in utero or in the neonatal period. In five cases (Table III; cases 15 to 19) both babies survived the neonatal period; one infant died at the age of 6 months.

The mean gestational age at initial examination in the nine pregnancies in which at least one child survived (21<sup>+3</sup> weeks) was similar to that of the 10 pregnancies in which both twins died (21<sup>+6</sup> weeks). However, unsuccessful pregnancies were associated with a greater intertwin disparity in abdominal circumference at initial examination (Fig. 1; 33% compared with 15% in successful pregnancies). Furthermore, in pregnancies with poor outcomes the mean volume of amniotic fluid removed at each procedure was higher (3200 ml compared with 2300 ml in successful pregnancies).

### Comment

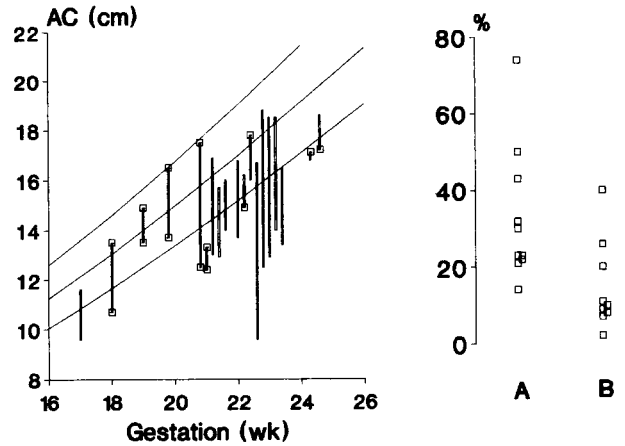
In twin pregnancies with acute second-trimester polyhydramnios treated by amniocentesis the overall fetal survival rate of 37% compares favorably with the results of series in which there was no antenatal intervention (Table I). The most likely mechanism by which decompression amniocentesis may improve survival is by prolongation of pregnancy through prevention of the polyhydramnios-mediated risk of spontaneous abortion or very premature delivery. It is also possible that with advancing gestation and increasing fetoplacental blood volume the relative significance of the hemodynamic effects of placental anastomoses is reduced. In this respect repeated amniocenteses may, at least in

Donor		Recipient		Difference in abdominal circumference (%)
Outcome	wk	Outcome	wk	
SA	23	SA	23	30
SA	23	SA	23	30
SA	24	SA	24	50
SA	24	SA	24	23
IUD	19	IUD	19	21
IUD	28	IUD	29	74
NND	26	NND	26	23
NND	28	IUD	28	22
IUD	29	NND	29	43
NND	31	IUD	30	14
LB	31	IUD	26	9
LB	30	IUD	26	8
LB	27	NND	27	11
NND	30	LB	30	2
LB	28*	LB	28	40
LB	29	LB	29	7
LB	35	LB	35	20
LB	36	LB	36	26
LB	37	LB	37	10

some cases, allow the fetal cardiovascular system to out-grow the deleterious effect of placental anastomosis.<sup>22</sup>

These data challenge the assertion that in twin-twin transfusion syndrome the need for decompression is a poor prognostic feature and that treatment by amniocentesis adds nothing to the management of this condition.<sup>1,9</sup> However, the apparent beneficial effect of decompression amniocentesis may merely reflect differences in reported study populations. Thus retrospective studies on the conservative management of twin-twin transfusion syndrome often use the criterion of a major disparity in fetal weight to identify the population from hospital records. In contrast, prospective intervention studies tend to select patients purely on the basis of polyhydramnios, and the issue of disparity in fetal weight is generally dealt with in a less stringent manner. Our data indicate that the greater the disparity in size between twins at initial examination the worse the prognosis. The reported outcome of conservative management is poorer than that of interventional management (Table I); the difference may be partly explained by the inclusion of pregnancies with larger intertwin differences in the conservatively managed group. This, coupled with the phenomenon of reporting bias (a greater likelihood to publish cases in which intervention appeared to be successful) may have exaggerated the apparent advantages of treatment.

The association between poor outcome and large intertwin differences in size and the need for drainage of larger volumes of amniotic fluid is presumably a consequence of the severity of the underlying disease. Twin-twin transfusion syndrome is traditionally be-



**Fig. 1.** Fetal abdominal circumferences (AC) in 19 twin pregnancies with acute second-trimester polyhydramnios treated with decompression amniocenteses plotted on reference range for gestation (left). Of 38 fetuses, 24 died in utero or in neonatal period and 14 survived (left, boxes). Intertwin difference in abdominal circumference at initial examination (expressed as percentage of smaller twin) was greater in pregnancies resulting in deaths of both babies (A) than in pregnancies in which one or both babies survived (B; right).

lieved to be caused by the unbalanced shunting of blood from donor to recipient, resulting in anemia and polycythemia, respectively. However, fetal blood sampling by cordocentesis has recently demonstrated that there are no major intertwin differences in hemoglobin concentration, and an alternative hypothesis has been suggested regarding the pathogenesis of this condition.<sup>23</sup> Both the severe early onset growth retardation in the donor and the polyhydramnios in the recipient twin may be consequences of uteroplacental insufficiency affecting the donor twin. Increased peripheral resistance in the placental circulation of the donor twin would promote the shunting of blood to the recipient twin through the vascular anastomoses that are invariably present in all monochorionic twin pregnancies.<sup>24</sup> The recipient twin is able to dispose of the additional fluid load by increased urine production,<sup>22</sup> but the protein and cellular components remain in its circulation to create an increase in colloid osmotic pressure that causes water to move from the maternal compartment across the placenta. Thus volume overload and diuresis continue, and a vicious cycle is established. The more severe the uteroplacental insufficiency, the earlier the appearance of symptoms, the smaller the donor twin, the larger the intertwin disparity in size, the worse the polyhydramnios, and the poorer the prognosis.

Increased intrauterine pressure as a consequence of marked polyhydramnios would be expected to compromise the placental circulation further. Since we analyzed our results, Elliott et al.<sup>25</sup> have reported a perinatal survival rate of 79% in twin-twin transfusion syndrome treated with repeated amniocenteses; they

attribute the high survival rate to improved placental blood flow after decompression.<sup>25</sup> The lower rate of fetal salvage in our series may be caused by differences in the two study populations because the treatment protocols appear to have been similar.

Selective feticide has been suggested as an alternative form of therapy in twin-twin transfusion syndrome.<sup>26</sup> Spontaneous intrauterine death of one twin may to some extent represent a parallel situation with regard to the likely outcome in the surviving fetus. In three of the five cases in our series in which one fetus was dead at the time of initial examination at 21 to 27 weeks' gestation, there was gradual resolution in polyhydramnios and the healthy cotwins were born 9 to 12 weeks later; in one case hydropic changes resolved in the weeks after initial examination (Table II). However, in another two cases the surviving twin developed ventriculomegaly. Although cerebral damage in surviving twins has been attributed to disseminated intravascular coagulation after the release of thromboplastin from the dead twin, this may not be the underlying mechanism in all cases; we have also observed ventriculomegaly caused by intraventricular hemorrhage in one donor fetus while both twins were alive. In five of the pregnancies treated with amniocentesis one of the fetuses died; in none of these cases was there an obvious improvement in either the polyhydramnios or the condition of the surviving twin. Indeed, in three cases the condition of the other twin deteriorated, and the baby died either in utero or in the neonatal period.

Laser occlusion of placental anastomosis<sup>27</sup> may convincingly be shown to improve the outcome of twin-twin transfusion syndrome appearing in the second trimester of pregnancy. In the meantime, we recommend decompression amniocentesis as an easy and relatively safe option providing some hope in an otherwise hopeless situation.<sup>10</sup> Nevertheless, the value of such treatment can only be established if factors of prognostic significance are clearly defined. Intertwin disparity in abdominal circumference at initial examination appears to be one such factor and should be taken into account when considering the apparent efficacy of therapy.

## REFERENCES

- Chescheir NC, Seeds JW. Polyhydramnios and oligohydramnios in twin gestations. *Obstet Gynecol* 1988;71:882-4.
- Brown DL, Benson CB, Driscoll SG, Doubilet PM. Twin twin transfusion syndrome: sonographic findings. *Radiology* 1989;179:61-3.
- Elejalde BR, Elejalde MM, Wagner AM, Lebel RR. Diagnosis of twin to twin transfusion syndrome at 18 weeks of gestation. *JCU* 1983;11:442-6.
- Patten RM, Mack LA, Harvey D, Cyr DR, Pretorius DH. Disparity of amniotic fluid volume and fetal size: problem of the stuck twin—U.S. studies. *Radiology* 1989;172:153-7.
- Pretorius DH, Manchester D, Barkin S, Parker S, Nelson TR. Doppler ultrasound of twin transfusion syndrome. *J Ultrasound Med* 1988;7:117-24.
- Urig MA, Clewell WH, Elliot GP. Twin-twin transfusion syndrome. *AM J OBSTET GYNECOL* 1990;163:1522-6.
- Weir PE, Ratten GJ, Beischer NA. Acute polyhydramnios: a complication of monozygous twin pregnancy. *Br J Obstet Gynaecol* 1979;86:849-53.
- Wittman BK, Baldwin VJ, Nichol B. Antenatal diagnosis of twin transfusion syndrome by ultrasound. *Obstet Gynecol* 1981;58:123-7.
- Bebbington MW, Wittmann BK. Fetal transfusion syndrome: antenatal factors predicting outcome. *AM J OBSTET GYNECOL* 1989;160:913-5.
- Feingold M, Cetrulo CL, Newton ER, Weiss J, Shagr C, Shmoys S. Serial amniocentesis in the treatment of twin to twin transfusion syndrome complicated with acute polyhydramnios. *Acta Genet Med Gemellol* 1986;35:107-13.
- Brennan JN, Diwan RV, Rosen MG, Bellon EM. Fetofetal transfusion syndrome: prenatal ultrasonographic diagnosis. *Radiology* 1982;143:535-6.
- Brown GR. Acute hydramnios treated by abdominal paracentesis. *J Obstet Gynaecol Br Emp* 1958;65:61-3.
- Brown GR. Letter. *Br J Obstet Gynaecol* 1980;87:255.
- Brown GR, Macaskill S. Acute hydramnios, with twins, successfully treated by abdominal paracentesis. *Br Med J* 1961;1:1739.
- Danziger RW. Twin pregnancy with acute hydramnios treated by paracentesis uteri. *Br Med J* 1948;2:205-6.
- Erskin JP. A case of acute hydramnios successfully treated by abdominal paracentesis. *J Obstet Gynaecol Br Emp* 1944;51:549-51.
- Gonsoulin W, Moise KJ, Kirshon B, Cotton DB, Wheeler JM, Carpenter RJ. Outcome of twin-twin transfusion diagnosed before 28 weeks of gestation. *Obstet Gynecol* 1990;75:214-6.
- Mills WG. Letter. *Br J Obstet Gynaecol* 1980;87:256.
- Montan S, Jorgensen C, Sjoberg N. Amniocentesis in treatment of acute polyhydramnios in twin pregnancies. *Acta Obstet Gynecol Scand* 1985;64:537-9.
- Nageotte MP, Hurwitz SR, Kaupke CJ, Vaziri ND, Pandian MR. Atriopeptin in the twin transfusion syndrome. *Obstet Gynecol* 1989;73:867-70.
- Schneider KTM, Vetter K, Huch R, Huch A. Acute polyhydramnios complicating twin pregnancies. *Acta Genet Med Gemellol (Roma)* 1985;34:179-84.
- Rosen D, Rabinowitz R, Beyth Y, Feijgin MD, Nicolaides KH. Fetal urine production in normal twins and in twins with acute polyhydramnios. *Fetal Diagn Ther* 1990;5:57-60.
- Saunders NJ, Snijders RJM, Nicolaides KH. Twin-twin transfusion syndrome in the second trimester is associated with small intertwin hemoglobin differences. *Fetal Diagn Ther* 1991;6:34-6.
- Robertson EG, Neer KJ. Placental injection studies in twin gestation. *AM J OBSTET GYNECOL* 1983;147:170-4.
- Elliott JP, Urig MA, Clewell WH. Aggressive therapeutic amniocentesis for treatment of twin-twin transfusion syndrome. *Obstet Gynecol* 1991;77:537-44.
- Wittmann BK, Farquharson DF, Thomas WDS, Baldwin VJ, Wadsworth LD. The role of feticide in the management of severe twin transfusion syndrome. *AM J OBSTET GYNECOL* 1986;155:1023-6.
- De Lia JE, Cruikshank DP, Keye WR. Fetoscopic neodymium: YAG laser occlusion of placental vessels in severe twin-twin transfusion syndrome. *Obstet Gynecol* 1990;75:1046-53.